Bony Pelvic

The Bony Pelvis

Learning Objectives:

By the end of this lecture the nursing student will be able to:

1. Describe the parts of female bony pelvic.
2. Deferanciate between true and false pelvice.
3. List defferant types of pelcvices.
4. Deferanciate between male amd female pelvice.

Outlines:

- Composion of bony pelvice.
- Diameters of pelvic
- Types of pelvic.
- The differences between the male and female pelvis.
- Blood supply, lymph drainage and nerve supply
- The Pelvic Floor Muscle

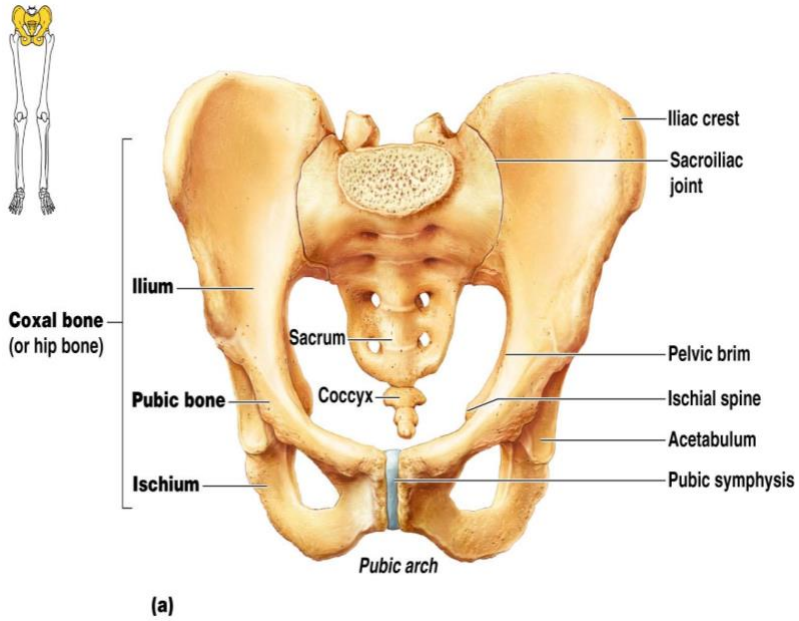

The bony pelvis composes of:

1. **2 Innominate bones,** each one composed of Illium, Ischium**, Pubis**
2. **One Sacrum**
3. **One Coccyx**

The female bony pelvis is divided into:

- **False pelvis**: above the pelvic brim and has no obstetric importance.
- **True pelvis**: below the pelvic brim and related to the child -birth.

The True Pelvis: It is composed of **inlet, cavity, and outlet.**

The Pelvic inlet (brim) Boundaries

1. Sacral promontory posteriorly.
2. Sacroiliac joints.
3. Iliopectineal lines.
4. Pubic crests.
5. Upper border of symphysis pubis anteriorly.

Diameters of Pelvic inlet Antero-posterior diameter (true conjugate) = 11cm

- From the tip of the sacral promontory to the upper border of the symphysis pubis.

  - **Obstetric conjugate = 10.5 cm**
    - from the tip of the sacral promontory to the most bulging point on the back of symphysis pubis which is about 1 cm below its upper border. It is the shortest antero-posterior diameter.
  - **Diagonal conjugate = 12.5 cm**
    - From the tip of sacral promontory to the lower border of symphysis pubis. i.e. 1.5 cm longer than the true conjugate.
  - **Oblique diameters: =12 cm**
    - From the sacroiliac joint to the left iliopectineal eminence.

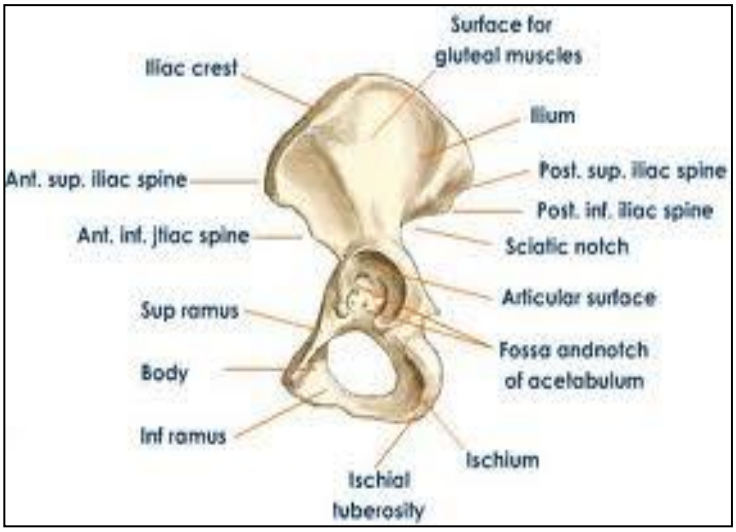

The Pelvic Cavity:

It is a segment, the boundaries of which are:

- The roof is the plane of pelvic brim,

- The floor is the plane of least pelvic dimension,
- Anteriorly the shorter symphysis pubis,
- Posteriorly the longer sacrum.

The Pelvic Outlet

❖ ***Obstetric outlet :It is a segment, the boundaries of which are:***

1. Anteriorly the lower border of symphysis pubis,
2. Posteriorly the coccyx.
3. Laterally the ischial spine

Diameters of pelvic outlet

- **Antero - posterior diameters: = 13 cm**
  - From the tip of the sacrum to the lower border of symphysis pubis in early labor it is 11cm, but during the second stage of labor when the head pushes the mobile coccyx backward 2cm. thus become 13 cm.
- **Transverse diameters: = 11 cm**
  - Between the inner aspects of the ischial tuberosities.
- **Bi-spinous diameter = 10.5 cm**
  - Between the tips of ischial spines. If this diameter is less than 9.5cm. there is nearly 50% chance for surgical intervention

Classification of Pelvic Types

1- Gynaecoid pelvis (50%):

The best type of female pelvis for normal delivery

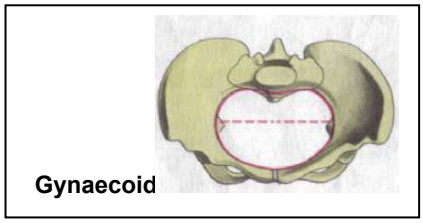

- It is the normal female type.
- Inlet is slightly transverse oval.
- Sacrum is wide.
- Side walls are straight with blunt ischial spines.

- Sacro-sciatic notch is wide.
- Subpubic angle is 90-100o.

2- Anthropoid pelvis (25%):

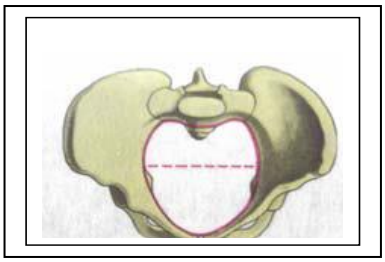

- It is ape -like type.
- All anteroposterior diameters are long.
- Sacrum is long and narrow.
- Sacro-sciatic notch is wide.
- Subpubic angle is narrow.

3- Android pelvis (20%): It is a **male** type.

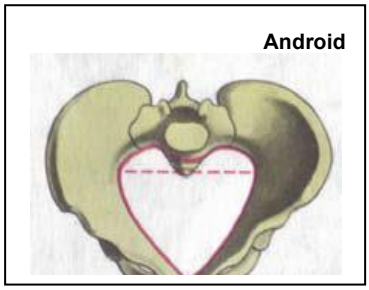

- Inlet is triangular or heart-shaped with anterior narrow apex.
- Side walls are converging (funnel pelvis) with projecting ischial spines.
- Sacro-sciatic notch is narrow.
- Subpubic angle is narrow <90o.

4- Platypelloid pelvis (5%):

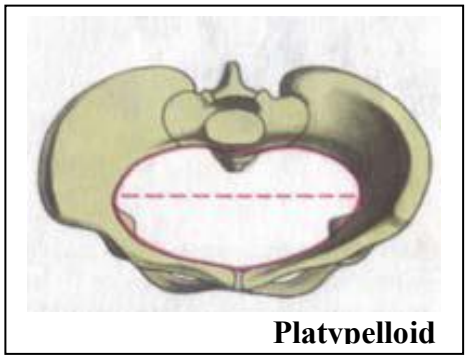

- It is a flat female type.
- All anteroposterior diameters are short.
- Sacro-sciatic notch is narrow.
- Subpubic angle is wide.
- All transverse diameters are long.

The differences between the male and female pelvis

Characteristics	Male Pelvis	Female Pelvis
1. Bones	Taller , heavier, and thicker	lighter , thin and more delicate
2. Size	smaller	Larger
3. Sacrum	Curved	Less curved
4. Ischial spine	Bigger	Smaller
5. Subpubic arch	Narrow	Wide
6. Pelvic inlet	Heart -shaped	oval-shaped
7. Pelvic cavity	Funnel shape	Less Funnel shape
8. pelvic outlet	smaller	larger
9. coccyx	Less movable	Movable

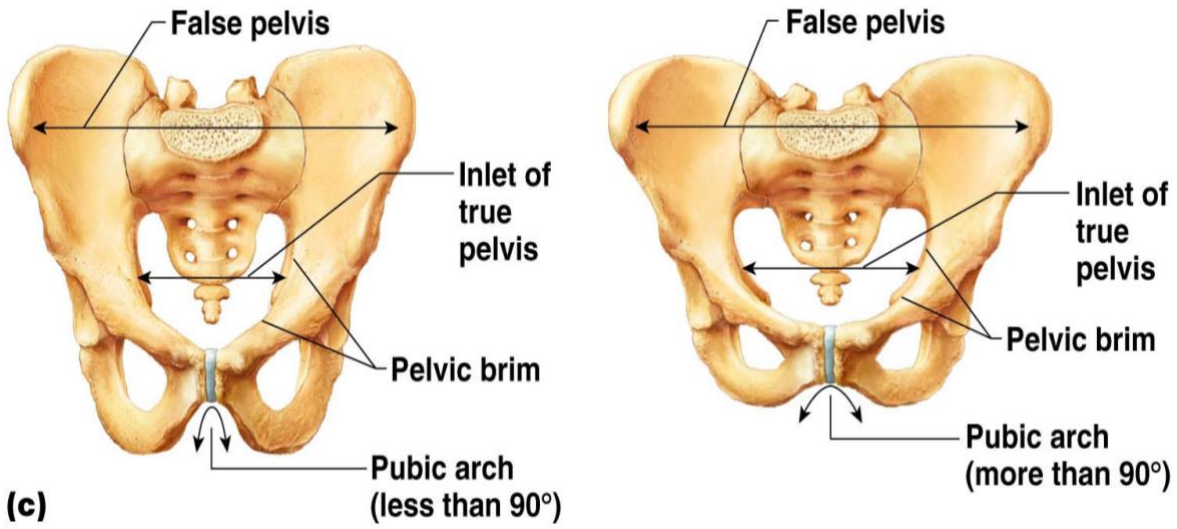

1. Intertuberous diameter accept 4 knuckles on pelvic exam

The Pelvic Floor Muscles

Function:

- It is important in providing support for pelvic viscera (organs), e.g. the bladder, intestines, the uterus (in females), and in maintenance of continence as part of the urinary and anal sphincters.
- It facilitates birth by resisting the descent of the presenting part, causing the fetus to rotate forwards to navigate through the pelvic girdle.

Identify the pelvic diaphragm and its components?

1. **The Pelvic Floor diaphragm :**

This is the soft tissue filling the pelvic bony outlet. It consists from above downwards

- The pelvic peritoneum
- The pelvic Fascia
- The levator ani muscle
- The perineal muscles
- Skin of the perineum

2 .The components of levator ani muscles :

- Pubococcygeus muscles
- Iliococcygeus muscles
- Puborectalis muscles

- ***Damage*** to the pelvic floor not only contributes to urinary **incontinence** but can lead to pelvic organ **prolapse.**
- ***Pelvic organ prolapse*** occurs in women when pelvic organs (e.g. the vagina, bladder, rectum, or uterus) protrude into or outside of the vagina.
- The pelvic floor muscles can be strengthened with **Kegel exercises**

Blood supply, lymph drainage and nerve supply

- Uterine arteries - branches of internal iliac arteries
- Venous drainage into internal iliac veins
- Lymph drains into aortic lymph nodes and groups of nodes associated with the iliac blood vessels.

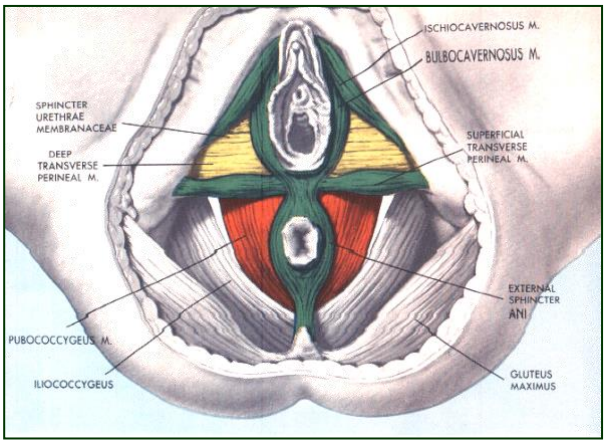

- Nerve supply sympathetic from the lumbar outflow - parasympathetic from sacral outflow a critical mass.

References

1. Cunningham, F. G., Leveno, K. J., Bloom, S. L., Dashe, J. S., Hoffman, B. L., Casey, B. M., & Spong, C. Y. (Eds.). (Current Edition). Williams Obstetrics. McGraw-Hill Education. (Considered a foundational reference in obstetrics, covering physiological changes in detail).
2. Lowdermilk, D. L., Perry, S. E., Cashion, M. C., & Alden, K. R. (Eds.). (Current Edition). Maternity and Women's Health Care. Elsevier. (Provides a comprehensive nursing perspective on maternal and child care, including physiological changes).
3. Ricci, S. S., Kyle, T., & Carman, S. (Current Edition). Maternity and Pediatric Nursing. Wolters Kluwer.
4. National Institutes of Health (NIH) - PubMed Central: (pmc.ncbi.nlm.nih.gov) An excellent database for searching recent scientific articles on "Physiological changes during pregnancy" or "Maternal adaptations in pregnancy."
5. American College of Obstetricians and Gynecologists (ACOG): (www.acog.org) Provides guidelines and resources for professionals and patients.
6. World Health Organization (WHO): (www.who.int) Offers global guidelines on maternal care and reproductive health.